

Evaluation of Common and Atypical Clinical Presentations of Tinea Faciei: A Cross-sectional Study from Barabanki, Uttar Pradesh, India

SUGANITA¹, DEEPIKA AGARWAL², SONAL SACHAN³, VANDANA YADAV⁴, HARSHIT JAISWAL⁵, DIVYA PRAJAPATI⁶

ABSTRACT

Introduction: Tinea faciei is a dermatophytic infection affecting the glabrous skin of the face. While it is less common than dermatophyte infections of other anatomical sites, tinea faciei has become more prevalent in recent years, being reported in Dermatology Outpatient Departments.

Aim: To enrich our understanding of tinea faciei with the intention of improving diagnostic accuracy and treatment outcomes.

Materials and Methods: The present cross-sectional study was conducted in the Department of Dermatology, Venereology and Leprosy, Hind Institute of Medical Sciences, Barabanki, Uttar Pradesh, India, from October 2022 to October 2023. Total 75 patients with the clinical diagnosis of tinea faciei were recruited and subjected to Potassium Hydroxide (KOH) preparation for direct microscopic examination. Epidemiological data, as well as, information on exposure to systemic and oral steroids, and previous treatment was collected. Different morphologies of tinea faciei, involved site on the face, severity of itching, and additional affected body areas were also noted. Coding, data entry, clearing and compiling were done in Microsoft Excel sheets, and statistical software including Statistical Package for the Social Sciences (SPSS) software version 29.0 was used for statistical analysis.

Results: The present study comprised 45 (60%) males and 30 (40%) females, with a mean age of 30.7 years. A total of 27

(36%) patients had pets at their homes, and 35 (46.6%) patients were involved in handling domestic animals. A family history was positive in 21 (28%) patients. The most common site in the face was the cheeks, affecting 45 (60%) patients, followed by areas around the eyes and nose in 26 (34.6%) patients each, the forehead in 23 (30.6%), and around the mouth and on the external ear in 22 (29.3%) patients each. The initial index lesion involving the face was found in 34 (45.3%) patients, while other sites were involved in 41 (54.6%) patients. The most common morphology included ill-defined margin, absence of scaling, the central clearing, pustular lesions, incomplete circle, psoriasiform and erosions. Steroid abuse was found in 73 (97.3%) patients, where most patients giving a history of only topical steroid usage.

Conclusion: The present study offers important insights into various aspects of tinea faciei, including its occurrence, epidemiology, risk factors, and the role of steroid abuse. The authors have described various common and atypical clinical morphologies and distributions of tinea faciei and recognising these atypical signs can help clinicians diagnose the condition early and initiate timely treatment. Moreover, the present study highlights that many patients use steroids in the form of topical, oral and injection to get quick relief, which can complicate the diagnosis.

Keywords: Risk factors, Steroid abuse, Tinea auricularis, Tinea incognito

INTRODUCTION

Dermatophytosis, a common fungal infection affecting 20-25% of the world population [1], is prevalent in tropical and subtropical regions, encompasses various clinical forms, with tinea cruris and corporis being the most common and prevalent presentation [1-3]. The prevalence of tinea in India is 27.6%, with tinea cruris and corporis accounting for 78% and 10% of cases, respectively [4]. However, tinea faciei has emerged as a noteworthy concern in dermatological practice. Tinea faciei is a superficial dermatophyte infection affecting the glabrous skin of the face, thus excluding the areas where moustache and beard grow in adult males [5]. In paediatric patients and females, the infection can appear anywhere on the face, including upper lips and chin. This condition poses diagnostic challenges due to its diverse clinical presentations.

The prevalence of tinea in India is currently 27.6%, with tinea faciei accounting for 1.8% of cases, indicating its significance within the dermatological landscape [4]. Moreover, the evolving clinical spectrum of tinea faciei, including atypical presentations that mimic other dermatoses, necessitates a deeper understanding of its epidemiology and associated risk factors. On review of the literature, most of the studies [1-4,6] have included all superficial

dermatophytic infections, with limited studies focusing only on tinea faciei [7-11].

The present study aimed to understand and highlight various morphological features (including the atypical presentations), sites of involvement, risk factors, and prevalence of steroid abuse among tinea faciei patients. This will enhance our understanding regarding the nature of the disease and our ability to treat patients better.

MATERIALS AND METHODS

The present cross-sectional study was conducted in the Department of Dermatology, Venereology and Leprosy, Hind Institute of Medical Sciences, Barabanki, Uttar Pradesh, India, from October 2022 to October 2023. Informed consent was obtained from the study participants.

Sample size calculation: The sample size was calculated using the formula:

$$n = Z_{\alpha/2} p (1-p) / E^2$$

p = prevalence or incidence

Z_{α} = Critical value of Z-score at corresponding α level of significance (at, $\alpha=5\%$, $Z_{\alpha}=1.96$)

$E = \text{Margin of error} = 3\% = 0.03$

$p = 1.8\% = 0.018$ (prevalence of Tinea faciei [4])

$n = (1.96)2 \times 0.018 (1 - 0.018) / (0.03)^2$

$n = 75.44 \approx 75$

Inclusion criteria: All consecutive patients with the clinical diagnosis of tinea faciei, irrespective of their age, who gave consent to participate, were recruited in the study and questioned regarding their disease.

Exclusion criteria: Patients who did not give consent and those with KOH-negative patients were excluded from the study.

A total of 112 patients were enrolled, of which 75 were included in the study and 37 were excluded. Patients with KOH examination showing positive findings for the presence of dermatophytes were included in the study.

Study Procedure

Information was collected on age, sex, occupation, total duration of the disease, contact with pets and cattle, family history, exposure to systemic and oral steroids, and previous treatment were collected. Patients were inquired regarding the appearance of the first lesion of tinea, (labelled as index lesion) and noted if present on the face or the site other than the face.

Samples were obtained for direct microscopic examination with KOH. Skin scraping from the periphery of the lesions was collected and subjected to direct microscopic examination with 10% KOH. Different morphologies of tinea faciei, site of involvement on the face, severity of itching, and other affected sites were also noted. Itching intensity was measured using the Numerical Rating Scale (NRS) and categorised into no (0 points), mild (1-3 points), moderate (4-6 points), severe (7-8 points) and very severe pruritus (9-10 points).

STATISTICAL ANALYSIS

Coding, data entry, clearing and compiling were done in Microsoft Excel sheets. Appropriate statistical software, including SPSS software version 29.0, was used for statistical analysis.

RESULTS

The epidemiological data, including gender, age distribution, presence of pets, and exposure to cattle/animals, is summarised in [Table/Fig-1]. The present study comprised 45 males and 30 females, with a mean age of 30.7 years (range: 8 months to 60 years) and a Standard

Variables	n (%)
Gender	
Male	45 (60)
Female	30 (40)
Age (years)	
<10	03 (4)
10-19	16 (21.3)
20-39	34 (45.3)
40-59	20 (26.6)
>60	02 (2.6)
Presence of pets	
Yes	27 (36)
No	48 (64)
Exposure to cattle/animals	
Yes	35 (46.6)
No	40 (53.3)
Family history	
Present	21 (28)
Absent	54 (72)

[Table/Fig-1]: Epidemiological profile of patients.

Deviation (SD) of 13.92. There were three children below 10 years of age, with peak incidence observed in the age group of 16-20 years, and only two elderly patients aged 60 years.

The site of involvement on the face, various morphological presentations, and severity of itch is summarised in [Table/Fig-2]. Sites other than the face, location of index lesion, presence of steroid abuse, methods of steroid abuse (injection, oral and topical), and description of topical steroid abuse are also mentioned.

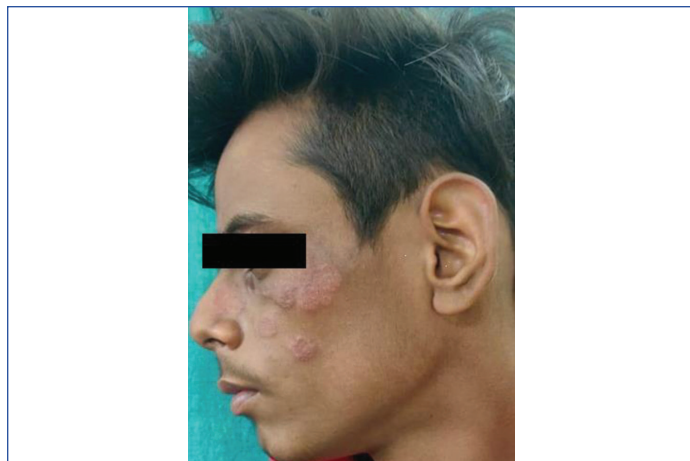Parameters	n (%)
Site	
Cheeks	45 (60)
Forehead	23 (30.6)
Around mouth	22 (29.3)
Nose	26 (34.6)
Around eyes	26 (34.6)
External ear	22 (29.3)
Morphology	
Central clearing	11 (14.6)
Ill-defined margin	30 (40)
Incomplete circle	05 (6.66)
No scaling	17 (22.6)
Eczematous	04 (5.33)
Psoriasiform	05 (6.66)
Pseudoimbricata	01 (1.33)
Pustular margin	03 (4)
Pustular lesions	08 (10.66)
Pityriasis rosea like	04 (5.33)
Erosive	05 (6.66)
Others like hypo/hyperpigmentation	35 (46.6)
Severity of Itching	
No itching	02 (2.6)
Mild	21 (28)
Moderate	17 (22.6)
Severe and very severe	35 (46.66)
Only face involved	10 (13.3)
Other sites involved along with face	65 (86.6)
Groin	27 (36)
Buttocks	20 (26.6)
Others (including abdomen, chest, inframammary, thigh, waist, legs, scalp, shoulder, foot)	18 (24)
Index lesions	
Face	34 (45.33)
Groin	14 (18.66)
Buttocks	11 (14.66)
Abdomen	4 (5.33)
Inframammary	2 (2.66)
Thigh	2 (2.66)
Back	2 (2.66)
Others (arm, chest, foot, neck, scalp, shoulder)	6 (8)
Steroid abuse	
Present	73 (97.3)
Absent	02 (2.6)
Description of topical steroids abuse	
Only steroids	10 (13.3)
Steroids + antibacterial	01 (1.33)
Steroid + antifungal	05 (6.66)
Steroid + antifungal + antibacterial	48 (64)

Method of steroid use	
Topical steroids	64 (85.3)
Oral steroids	25 (33.3)
Injectable steroids	02 (2.6)

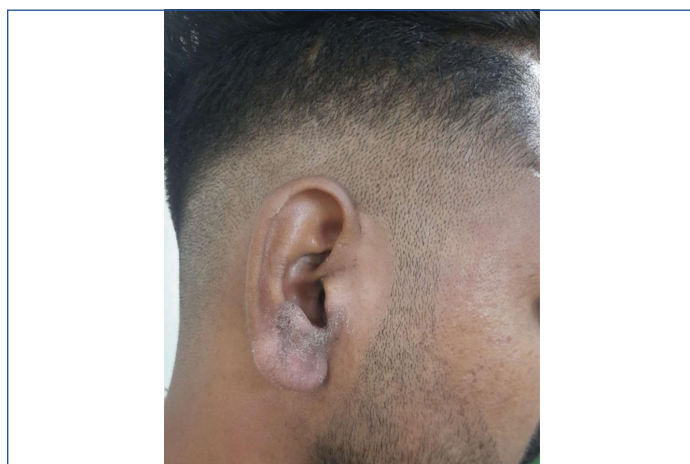
[Table/Fig-2]: Clinical manifestations of patients.

The risk factors associated with tinea faciei seen in the present study are other site involvement along with face: groin, 27 (36%), buttocks, 20 (26.6%), and others, 18 (24%) including abdomen (2), chest, inframammary area, thigh, waist, legs, scalp, shoulder, and foot. The most common occupation was housewives, 18 (24%) cases, followed by students, 15 (20%) cases, unemployed, 12 (16%) cases, farmers, 8 (10.6%) cases, labourers, 7 (9.3%) cases, shopkeepers, 5 (6.6%) cases, cooks, 4 (5.3%) cases and others, 6 (8%) cases. A positive family history was noted in 21 (28%) cases, exposure to pets in 27 (36%) cases, and exposure to cattle in 35 (46.6%) cases. Steroid abuse in the form of topical, oral, and injectable steroids was present in 73 (97.3%) cases. Co-morbidities, including diabetes and hypertension, were found in only eight patients.

Cheeks were the most commonly involved anatomical site on the face, and the most common morphological features noted in the present study were ill-defined margins, absence of scaling and central clearing [Table/Fig-3-8].



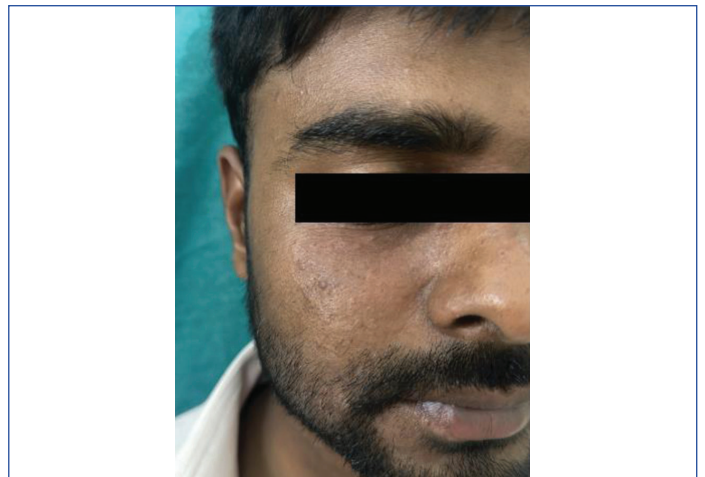[Table/Fig-3]: Tinea faciei- a superficial dermatophyte infection affecting the glabrous skin of the face.



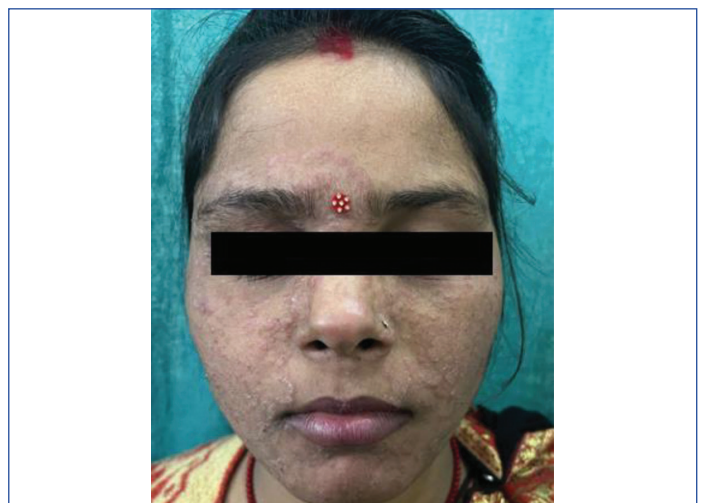[Table/Fig-4]: Tinea auricularis including the sole involvement of the ear with no sign of dermatophytosis on the face or elsewhere on the body.

DISCUSSION

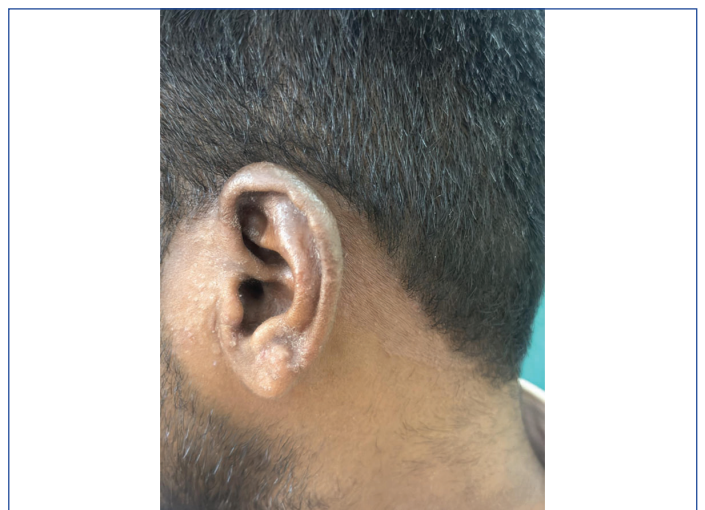Tinea faciei, historically viewed as a less common type of dermatophytosis compared to tinea corporis and cruris, has been receiving more focus lately because of its developing range of clinical spectrums and difficulties in diagnosis. The precise prevalence of tinea faciei cannot be determined due to the absence of community-based surveys, as most studies are conducted in hospitals [6]. In



[Table/Fig-5]: Periocular involvement of tinea lesions presenting only with the involvement of lower eyelids and completely sparing the upper one.



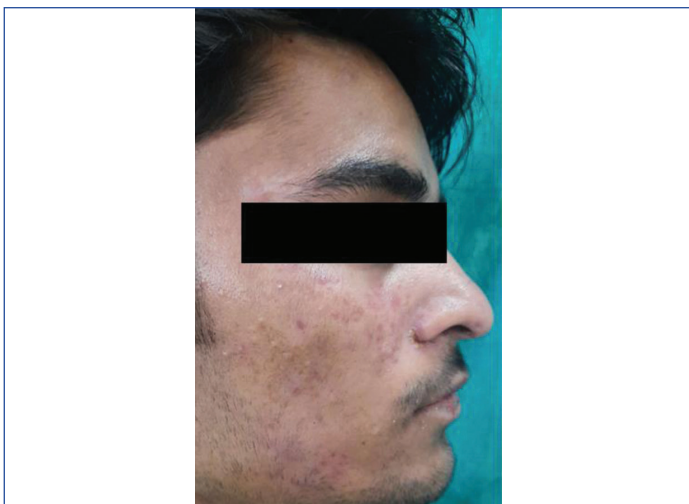[Table/Fig-6]: Tinea labialis, in which the facial lesions extend onto the upper lip.



[Table/Fig-7]: Lesions on the face and neck which also extended to the scalp.

addition, a few studies have indicated an increasing incidence of tinea faciei in both adults and children [4].

Several efforts have been made to further categorise tinea faciei based on the involvement of specific facial structures. Tinea auricularis includes the sole involvement of the ear with no signs of dermatophytosis on the face or elsewhere on the body [12]. In the present study, there was a single patient who fit this definition. Periocular involvement of tinea lesions, involving either the upper or lower eyelids, was not very uncommon. Approximately 34.6% of the subjects had periocular involvement, with most showing involvement of both the upper and lower eyelids, including canthi. One patient presented only with the involvement of lower eyelids, completely



[Table/Fig-8]: Tinea incognita- the presence of ill-defined margins, absence of scaling, and lack of central clearing, attributed to the inappropriate use of topical steroids.

sparing the upper one. Tinea labialis, with lip involvement, is a rare entity [12]. In the present study, although 22 patients had lesions around the mouth area, only a single patient had an extension of the tinea lesion onto the upper lip. One patient presented with lesions on the face and neck that also extended to the scalp.

In the present study, there were 45 males and 30 females. Other studies have found female predominance. Nicola A et al., studied 107 cases of tinea faciei over 20 years, which included 72 females and 35 males [7]. Another study, with a case series of 30 children with tinea faciei, had eight males and 22 females [8].

The age of the patients enrolled ranged from as young as eight months to as old as 60 years. The mean±SD age of the study participants was 30±13.92 years. The peak incidence of tinea faciei was observed in the age group of 16-20 years, emphasising the vulnerability of adolescents and young adults to this dermatophytosis, possibly due to factors such as increased social interactions, greater outdoor activities, and climate change leading to more perspiration over the face. The rise in tight-fitting and synthetic fabric clothing among this age group makes them more susceptible to developing dermatophytic infections in covered parts of the body, which can eventually lead to facial involvement. A positive family history is another reason for this because of the epidemic-like situation of dermatophytosis in India. Additionally, the misuse of topical steroids on the face for acne and pigmentation greatly disrupts the skin's defense mechanism against dermatophytes [6]. However, more research studies are needed in the future to validate these risk factors and investigate the susceptibility and vulnerability of young adults to tinea faciei.

The present findings also shed light on the epidemiological and risk factors associated with tinea faciei. The risk factors associated with tinea faciei seen in the present study are involvement of other sites (such as the groin and buttocks). The most common occupation among patients were housewives, followed by student. Positive family history, exposure to pets and cattle, and steroid abuse (in the form of topical, oral and injectable steroids) were also present. Co-morbidities, including diabetes and hypertension, were found in eight patients. The significant association between other site involvement, pet ownership, occupational exposure to animals, positive family history of tinea infection, tight-fitting clothing, lower socio-economic status and immunosuppressive conditions like diabetes mellitus underscores the role of environmental and genetic factors in disease susceptibility. Singh S et al., conducted a case-control study to assess risk factors for chronic and chronic-relapsing tinea corporis, tinea cruris, and tinea faciei [13]. They found a positive association with pre-existing diabetes mellitus, family history of tinea, and personal history of cooking food.

The most commonly involved anatomical site in the face is the cheeks, followed by the areas around the eyes and nose, the

forehead, around the mouth and the external ear. Kushwaha P et al., reported that the most common site on the face in children and females is the cheek, while in males, it is the forehead and temple area [9]. Periocular dermatophytic infection is an extremely rare condition, and this atypicality further increases with isolated involvement [14]. Additionally, the diagnosis of periocular tinea is often challenging due to its lack of conventional morphology in most cases [14].

Ten of these patients had tinea affecting only the face, while the involvement of sites other than the face was seen in the rest of 65 patients. Dermatologists can be perplexed when diagnosing due to the involvement of the cheek and nose or when tinea faciei is the sole affection, as symptoms can worsen with sun exposure and may mimic other photodermatoses, like rosacea and cutaneous lupus erythematosus. This similarity frequently results in misdiagnosis and a worsening of symptoms from wrongly prescribed topical corticosteroids [10].

Amongst those with sites other than face, the most commonly affected site was the groin, in 27 patients, then the buttocks in 20 patients, followed by other sites like the inframammary area, thighs and abdomen. The initial index lesion involving the face was found in 34 patients. Previous literature has documented cases of dermatophytic infections occurring simultaneously in other body sites alongside tinea faciei, which aligns with what the authors have observed [10]. It's important to note, however, that the index lesion was reported on the face in approximately fifty percent of our patients, which is an exposed area. This contrasts with the earlier belief that dermatophytes prefer occluded areas of the body and later involve the face following auto-inoculation [11].

The present study evaluated the various classical and atypical clinical morphologies of tinea faciei. The classical morphology of tinea is defined as well-defined, centrifugally spreading annular lesions with central clearing and an advancing scaly border. In the present study, central clearing was seen in only 11 patients. The most common atypical morphology of the lesions showed an ill-defined margin in 30 patients, followed by an absence of scaling in 17 patients, pustular lesions in eight patients, incomplete circle, psoriasiform lesions and erosions, which were seen in five patients each. Pityriasis rosea-like and eczematous lesions were noted in four patients each, while pustular margins were observed in three patients. The severity of itching varied from mild in 21 patients to moderate in 17 patients, and severe to very severe in 35 patients. One notable observations from the present study is the diverse clinical presentations of tinea faciei, ranging from typical erythematous plaques with well-defined borders to atypical morphologies mimicking other dermatological conditions. This diversity underscores the importance of clinical acumen and mycological confirmation in accurately diagnosing tinea faciei, especially in cases with ambiguous clinical features. The presence of ill-defined margins, absence of scaling and lack of central clearing, commonly observed in the present study patient cohort, highlight the phenomenon of tinea incognita, often attributed to the inappropriate use of topical steroids. Tinea faciei has been described to have a higher incidence in tinea incognito compared to other dermatophytoses [15-17]. Dermatophytosis typically follows a prolonged non-inflammatory course and mainly affects the superficial keratinous layers of the skin. It seldom penetrates beneath the skin's surface, leading to atypical clinical manifestations. Although the primary cause is thought to be topical corticosteroids, which reduce local immunity and enable fungi to invade beyond the superficial skin layers, it is important to consider the aggressiveness of the invading pathogen, the systemic immunity of the host, complicated facial anatomy of skin, and vulnerability of face to more sun exposure in contributing to the unusual presentations of tinea faciei [4,10,18-20].

This corresponds to several such propensities of tinea faciei where it mimicked conditions such as discoid lupus erythematosus [21],

rosacea [22], impetigo [23], polymorphic light eruptions [24] and Sweet's syndrome [18].

Tinea faciei is a condition with complex symptoms that necessitates thorough history-taking to identify contact with animals. A physical examination is crucial to check for involvement of other areas, which can provide important clues [20]. Microbiological examination and histopathology are important for detecting deeply hidden infections and to rule out closely resembling facial dermatoses [6,20]. Creating a KOH mount is a necessary, quick and straightforward step for all suspected facial lesions, whether scaly or non scaly. Mycological culture is used to confirm the diagnosis and provide reliable evidence to support claims in cases where the KOH microscopy result is negative [20].

Steroid abuse was found in 73 patients, with most patients giving a history of only topical steroid usage. A few patients also provided a history of oral or injectable steroid usage. Of particular concern is the high prevalence of steroid abuse among the present study patient cohort, with the majority reporting the use of topical corticosteroids, either alone or in combination with antifungal agents. This highlights the widespread misuse of topical steroids in dermatological practice, often driven by patients' desire for rapid symptomatic relief and cosmetic improvement. The consequences of steroid abuse in tinea faciei, including disease exacerbation, altered clinical morphology and therapeutic resistance, underscore the imperative for judicious prescribing practices and patient education regarding the appropriate use of topical corticosteroids.

Limitation(s)

The fungal culture was not performed, and it was an Outpatient Department-based study, and not a true representation of the population.

CONCLUSION(S)

In conclusion, the present study offers important insights into various aspects of tinea faciei, including its occurrence, epidemiology, risk factors and the role of steroid abuse. The authors have observed that tinea faciei can show unusual symptoms, and recognising these atypical signs can help clinicians diagnose the condition early. This is particularly useful when the disease does not match the typical symptoms and may be mistaken for other conditions. Moreover, the study highlights that many patients use steroids to get quick relief, which can complicate the diagnosis. Future research with larger groups of people is needed to build on these findings. Such studies could help us gain a deeper understanding of tinea faciei, improve diagnostic techniques and develop better treatment strategies.

REFERENCES

- [1] Havlickova B, Czaika VA, Friedrich M. Epidemiological trends in skin mycoses worldwide. *Mycoses*. 2008;51(4):02-15.
- [2] Kumar U, Chauhan MP, Varma K. A clinico epidemiological study of dermatophytosis in a tertiary care center, Ujjain. *IP Indian J Clin Exp Dermatol*. 2019;5(1):89-92.
- [3] Peerapur BV, Inamdar AC, Pushpa PV, Srikant B. Clinicomycological study of dermatophytosis in Bijapur. *Indian J Med Microbiol*. 2004;22(4):273-74.
- [4] Lakshmanan A, Ganeshkumar P, Mohan SR, Hemamalini M, Madhavan R. Epidemiological and clinical pattern of dermatomycoses in rural India. *Indian J Med Microbiol*. 2015;33:134-36.
- [5] Lin RL, Szepletowski JC, Schwartz RA. Tinea faciei, an often deceptive facial eruption. *Int J Dermatol*. 2004;43(6):437-40.
- [6] Verma SB, Panda S, Nenoff P, Singal A, Rudramurthy SM, Uhrlass S, et al. The unprecedented epidemic-like scenario of dermatophytosis in India: I. Epidemiology, risk factors and clinical features. *Indian J Dermatol Venereol Leprol*. 2021;87(2):154-75.
- [7] Nicola A, Laura A, Natalia A, Monica P. A 20-year survey of tinea faciei. *Mycoses*. 2010;53(6):504-08.
- [8] Juan MF, Carlos GS. Tinea Faciei in children: A case series at the Instituto Nacional de Salud del Niño-Breña (Lima-Peru). *Clinical Medicine Research*. 2022;11:70-73.
- [9] Kushwaha P, Thakur R, Kumar H, Kalsi AS. Clinical Manifestations and Diagnostic Challenges of Tinea faciei. *Int J Curr Microbiol App Sci*. 2017;6(12):1286-94.
- [10] Khaled A, Chtourou O, Zeglouli F, Fazaa B, Jones M, Kamoun MR. Tinea faciei: A report on four cases. *Acta Dermatol venerol Alp Pannonica Adriat*. 2007;16(4):170-73.
- [11] Nenoff P, Mügge C, Herrmann J, Keller U. Tinea faciei incognito due to *Trichophyton rubrum* as a result of autoinoculation from onychomycosis. *Mycoses*. 2007;50(2):20-25.
- [12] Verma S, Vasani R, Gupta S. Involvement of little discussed anatomical locations in superficial dermatophytosis sundry observations and musings. *Indian Dermatol Online J*. 2020;11(3):419-24.
- [13] Singh S, Verma P, Chandra U, Tiwary NK. Risk factors for chronic and chronic-relapsing tinea corporis, tinea cruris and tinea faciei: Results of a case-control study. *Indian J Dermatol Venereol Leprol*. 2019;85:197-200.
- [14] Finger Basak SA, Berk DR, Lueder GT, Bayliss SJ. Common features of periorcular Tinea. *Arch Ophthalmol*. 2011;129(3):306-09.
- [15] Sen SS, Rasul ES. Dermatophytosis in Assam. *Indian J Med Microbiol*. 2006;24(1):77-78.
- [16] Naglot A, Shrimali DD, Nath BK, Gogoi HK, Veer V, Chander J, et al. Recent trends of dermatophytosis in Northeast India (Assam) and interpretation with published studies. *Int J Curr Microbiol App Sci*. 2015;4(11):111-20.
- [17] Surendran K, Bhat RM, Bolor R, Nandakishore B, Sukumar D. A clinical and mycological study of dermatophytic infections. *Indian J Dermatol*. 2014;59(3):262-67.
- [18] Viera MH, Costales SM, Regalado J, Alonso-Llamazares J. Placas faciales inflamatorias. *Actas Dermosifiliogr*. 2013;104(01):75-76.
- [19] Serarslan G. Pustular psoriasis-like tinea incognito due to *Trichophyton rubrum*. *Mycoses*. 2007;50(6):523-24.
- [20] Zhuang KW, Dai YL, Ran YP, Lama J, Fan YM. Tinea faciei on the right eyebrow caused by *Trichophyton interdigitale*. *An Bras Dermatol*. 2016;91(6):829-31.
- [21] Meymandi S, Wiseman MC, Crawford RI. Tinea faciei mimicking cutaneous lupus erythematosus: A histopathologic case report. *J Am Acad Dermatol*. 2003;48(2):S7-S8.
- [22] Gorani A, Schiera A, Oriani A. Case report. Rosacea-like Tinea incognito. *Mycoses*. 2002;45(3-4):135-37.
- [23] Belmokhtar Z, Djaroud S, Matmour D, Merad Y. Atypical and Unpredictable Superficial Mycosis Presentations: A Narrative Review. *J Fungi (Basel)*. 2024;10(4):295.
- [24] Jorquera E, Moreno JC, Camacho F. Tinea faciei: Étude épidémiologique [Tinea faciei: Epidemiology]. *Ann Dermatol Venereol*. 1992;119(2):101-04.

PARTICULARS OF CONTRIBUTORS:

1. Associate Professor, Department of Dermatology, Venereology and Leprosy, Hind Institute of Medical Sciences, Barabanki, Uttar Pradesh, India.
2. Associate Professor, Department of Dermatology, Venereology and Leprosy, Hind Institute of Medical Sciences, Barabanki, Uttar Pradesh, India.
3. Assistant Professor, Department of Dermatology, Venereology and Leprosy, Hind Institute of Medical Sciences, Barabanki, Uttar Pradesh, India.
4. Assistant Professor, Department of Dermatology, Venereology and Leprosy, Hind Institute of Medical Sciences, Barabanki, Uttar Pradesh, India.
5. Junior Resident, Department of Dermatology, Venereology and Leprosy, Hind Institute of Medical Sciences, Barabanki, Uttar Pradesh, India.
6. Junior Resident, Department of Dermatology, Venereology and Leprosy, Hind Institute of Medical Sciences, Barabanki, Uttar Pradesh, India.

NAME, ADDRESS, E-MAIL ID OF THE CORRESPONDING AUTHOR:

Dr. Vandana Yadav,
Assistant Professor, Department of Dermatology, Venereology and Leprosy, Hind Institute of Medical Sciences, Barabanki-225001, Uttar Pradesh, India.
E-mail: drvandana016@gmail.com

PLAGIARISM CHECKING METHODS: [Jain H et al.]

- Plagiarism X-checker: Jul 15, 2024
- Manual Googling: Oct 12, 2024
- iThenticate Software: Oct 14, 2024 (8%)

ETYMOLOGY: Author Origin

EMENDATIONS: 9

AUTHOR DECLARATION:

- Financial or Other Competing Interests: None
- Was Ethics Committee Approval obtained for this study? No
- Was informed consent obtained from the subjects involved in the study? Yes
- For any images presented appropriate consent has been obtained from the subjects. Yes

Date of Submission: **Jun 18, 2024**
Date of Peer Review: **Aug 06, 2024**
Date of Acceptance: **Oct 16, 2024**
Date of Publishing: **Jan 01, 2025**